

IMAGING PERFORMED BY

IntraPet.com



Clinical Sonography & Telecytology

EDUCATIONAL TELECONSULTATION SERVICES™

1-800-838-4268 info@sonopath.com SonoPath.com

PATIENT

Rocket Bardos

SPECIES

Feline

BREED

DSH

SEX

FS

AGE

2015

WEIGHT

8.8lbs

INTERPRETED BY

Maggie Machen Lamy,
DVM, DACVIM
(Cardiology)

HOSPITAL NAME

Cat Hospital at Towson

REFERRING VET

Dr. Brunt

INVOICE

24106

DATE

5/9/22

PRESENTING CLINICAL SIGNS

History: Heart murmur grade 3; left atrial enlargement.
Pertinent abnormal PE/Chem/CBC/UA Results: Chest rads suggests left atrial enlargement; lungs clear and no signs of CHF.
Current medications: None.
Sedation used: Not required to complete full diagnostic ultrasound.
Pertinent previous ultrasound results: No previous.
STAT: Not requested.
Imaging performed by: Stephanie Pearce RDCS, RVT.

ECHOCARDIOGRAM FINDINGS

2D, m-mode, color flow and doppler imaging is available. The left ventricular wall is normal in dimension. Borderline LV dilation. There is a hyperechoic endocardium consistent with fibrosis. The left atrium is mildly dilated and bulbous in appearance. Mild MV thickening with mild prolapse. Mild to moderate double jet of mitral regurgitation. No obvious systolic anterior motion of the MV is seen. The right atrium is normal in size. The right ventricle appears normal. No TR. Blood flow through both the LVOT and RVOT are normal in velocity. No effusions or cardiac tumors are identified.

CARDIAC CHART

FELINE CARDIAC PARAMETERS	BODY WEIGHT (kg)	HR (BPM)	IVSd (cm) <small>(Moise, Pipers)</small>	LVIDd (cm) <small>(Moise, Pipers)</small>	LWVd (cm) <small>(Moise, Pipers)</small>	FS (%)	EF (%)
NORMAL PARAMETER	-----	150-240	3.5-0.55	<2 (mean 1.5)	3.5-0.55	35-67	80-100
PATIENT	4.0	191	0.38	1.78	0.34	56	88
FELINE CARDIAC PARAMETERS	LA/AO <small>(Boon)</small>	LA/AO HEART BASE (Swe) <small>(Abbott)</small>	LA 2D short axis Base view (cm) <small>(Abbott)</small>		LVOT VEL (m/s)	RVOT VEL (m/s)	E max (m/s)
NORMAL	<1.5	<1.3	<1.2		<1.6	<1.3	<0.9
PATIENT	NM	1.5	1.4		1.1	0.77	NM

Adapted from June Boon, Veterinary Echocardiography, 1998
Abbott J & MacLean H JVIM 2006;20: 111-119, Moise et al. Am J Vet Res 47:1476, 1986. Pipers et al. Am J Vet Res 40:882, 1979.

INTERPRETATION OF THE FINDINGS & FURTHER RECOMMENDATIONS

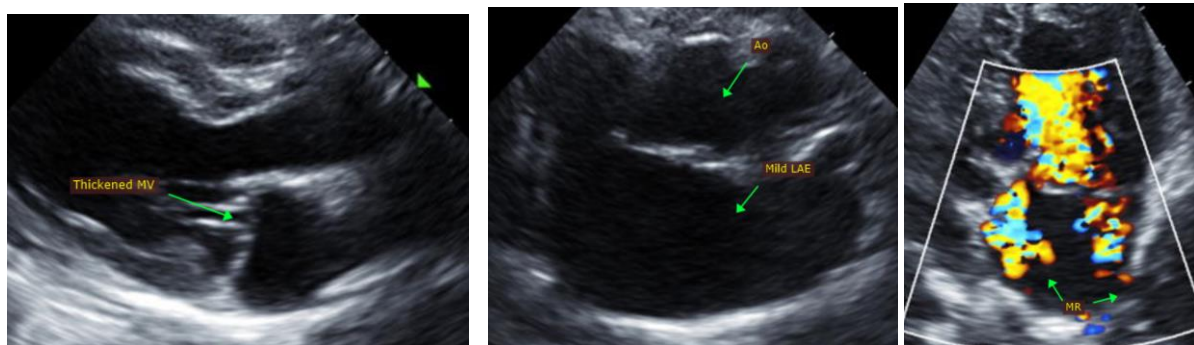
The cause of the murmur is mild to moderate mitral regurgitation. MR in cats is typically due to either MV dysplasia (abnormal morphology from birth) or secondary to abnormal valve motion (SAM/HOCM), the former being a possibility in this case. Mild MV thickening may also represent early valve disease similar to as seen in dogs, and serial monitoring is advised. The left atrium and ventricle are mildly enlarged, which is also concerning for potential progressive disease. No additional issues are identified, and the LV wall dimensions are normal.

Given a mild LA enlargement, no medications are indicated and simple follow up is advised. Risk is low for complication; however, long-term prognosis is guarded given the highly variable rates of progression of sub-clinical feline cardiomyopathy.

The risk for general anesthesia is low, however heart rate stimulating drugs such as atropine, glycopyrrolate should be avoided unless medically necessary. Even without significant pathology, there is a mildly elevated risk for fluid overload in this patient. Judicious IV fluid use is recommended.

Recheck echocardiogram is recommended in 6 months, sooner if development of any clinical signs.

IMAGES



The information and recommendations provided are based on the images presented by the referring veterinarian. No evaluation can be communicated regarding pathology that was not visible in the image/video clips provided.

Thank you for this referral. This report was generated using transcription software, and minor dictation errors may be present. If the clinical or image interpretation does not parallel your findings or if I can be of any further assistance please contact me.

Maggie Machen Lamy, DVM
Diplomate of the American College of Veterinary Internal Medicine (Cardiology)
info@sonopath.com